

Comprehensive Multidisciplinary Team Approach in the Treatment of Amelogenesis Imperfecta- Case Report

Anat Baniel^{1*}, Eldad Sharon², Shahar Menashe³ and Joseph Shapira¹

¹Department of Pediatric Dentistry, Hebrew University-Hadassah School of Dental Medicine, Israel

²Department of Prosthodontics, Hebrew University-Hadassah School of Dental Medicine, Israel

³Department of Endodontics, Hebrew University-Hadassah School of Dental Medicine, Israel

Article Information

Received date: Jun 13, 2017

Accepted date: Jul 18, 2017

Published date: Jul 21, 2017

*Corresponding authors

Anat Baniel, Department of Pediatric Dentistry, Hebrew University-Hadassah School of Dental Medicine, Jerusalem, Israel, Tel: 972-523978020; Fax: 02-6431747; Email: anat.baniel@gmail.com

Distributed under Creative Commons CC-BY 4.0

Keywords Amelogenesis imperfect; Revascularization; Hypodontia

Abbreviations AI: Amelogenesis Imperfecta

Abstract

Amelogenesis imperfecta comprises a group of hereditary enamel defects, characterized by enamel hypoplasia, hypomaturation, or hypocalcification of the teeth. We describe the treatment of an 8 year old boy diagnosed with autosomal dominant smooth hypoplastic AI. The patient had hypodontia and teeth with abnormal morphology; missing enamel, and a functional anterior crossbite. A treatment plan was implemented that improved function by restoring posterior teeth, improved esthetics by enhancing teeth appearance, eliminated functional deviation of the jaw, preserved the existing teeth, and promoted low cardiogenic nutrition and good oral hygiene. Treatment of young patients with AI should be oriented toward functional and esthetic rehabilitation.

Introduction

Amelogenesis Imperfecta represents a diverse group of hereditary conditions characterized by abnormalities in the amount, quality, and structure of enamel [1]. Witkop defined AI as a group of inherited disorders affecting the clinical appearance of enamel in some or all teeth, in both deciduous and permanent dentitions, that are not associated with known morphological or chemical changes in other body parts [1]. The classification most commonly used today was proposed by Witkop in 1989 [1]. Accordingly, 15 sub-types of AI are divided into 4 main classes: hypoplastic, hypomaturation, hypocalcified, and hypomaturation-hypoplastic with taurodontism. This article presents a multidisciplinary team approach to the treatment of autosomal dominant smooth hypoplastic amelogenesis imperfecta.

Case Report

A 9 year 8 month old boy, of Arab origin, the second of 3 siblings, presented with pain in his upper anterior teeth and recurring swelling of his upper lip. He does not take any medication regularly and has no known allergies. At the age of 3 years he underwent several extractions of teeth due to abscesses.

An extra-oral and intra-oral clinical examination was performed.

Extra-oral

The patient's head and neck were examined, his face was found to be symmetrical, his mouth opened correctly, no tenderness to touch was detected; he had competent lips, angle class I.

Intra-oral

Dentition – The patient had hypodontia. Some teeth were missing whereas others presented abnormal morphology. Enamel was largely missing, which resulted in a particular clinical appearance similar to teeth prepared for crowns: the dentition was spaced, the teeth were very small and smooth, and their color was yellow-orange-brown. In the upper jaw only the 4 incisors were present, and minimal tooth substance represented tooth #26 (permanent maxillary left first molar). In the lower jaw, with the exception of the central permanent incisors, all teeth were primary. On the right side there was only one primary molar, and on the left side, two. In addition, the tongue rested upon the alveolar ridges on both sides (Figure 1).

Dentoalveolar occlusion – functional anterior crossbite. In the absence of posterior teeth, while eating, the patient brought his lower teeth forward in order to make contact with the upper ones. Only under guidance for a retruded contact position was it apparent that tooth #21 (permanent maxillary left central) was almost tête à tête with tooth # 31 (permanent mandibular left central). Tooth # 11 (permanent maxillary right central) was in a 1 mm OJ and OB position with tooth # 41 (permanent mandibular left central).

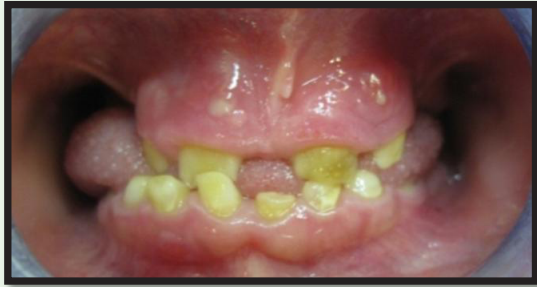

Figure 1: Frontal view of a 9 year 8 month old boy with Amelogenesis Imperfecta.

Soft tissue sinus tracts originated from teeth #11 & 21 (permanent maxillary right and left centrals) (Figure 1). Redness in the buccal vestibule presented near teeth #11 & 21, and tenderness to touch without any swelling.

Oral hygiene was good.

X-ray examination

The panoramic x-ray (Figure 2) revealed numerous pathologies: some teeth were unerupted and underwent intra-alveolar resorption (17, 16, 27, 26, 36, 46) others were missing (15, 35, 37, 47) and there was a lack of enamel (in some teeth there was complete loss and in others a very thin layer remained).

The treatment objectives were determined according to the following sequence: to improve function – by restoring the posterior teeth, adding posterior teeth (masticatory surfaces), and preserving the new vertical dimension; to improve esthetics – by improving the appearance of teeth and by adding artificial teeth to enhance the patient's smile; to eliminate functional deviation of his jaw; to preserve the existing teeth in the mouth as much as possible; to instill positive nutritional habits (low cardiogenic nutrition); and to create a positive attitude towards oral hygiene. The rationale behind the treatment sequence was prevention of the development of caries, and achievement of an esthetic result, which would grant the child the joy of a hearty smile. The esthetic solution also provided functional repair.

Since the patient was at high risk of developing caries [2], efforts were made to prevent any further caries activity. Oral hygiene

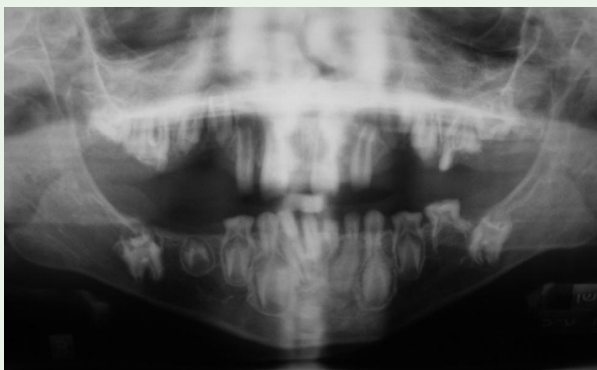


Figure 2: Panoramic X-ray.

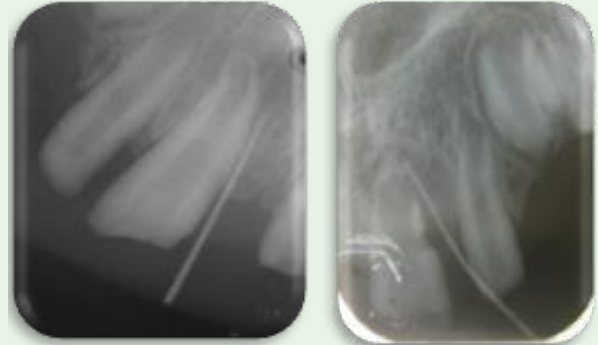


Figure 3: Tracing examination with gutta-percha to localize the origin of the sinus tracts.

instructions were implemented; the child was instructed to use a daily fluoride rinse 0.05% NaF [3,4]. Every dental visit to the clinic ended by application of Duraphat [5] (2.26% F, Colgate, Germany) on all the teeth. An additional preventive treatment was the sealing of the grooves in the erupting teeth and covering them fully later, when eruption was complete [6].

Teeth #11 and 21 (permanent maxillary right and left centrals) were non-vital with sinus tracts. They were therefore traced first with gutta-percha (Figure 3) to localize the origin of the sinus tracts, after which the pulp was treated. A conventional root canal treatment with gutta-percha was performed on tooth #11 (permanent maxillary right central), and a “revascularization” technique on tooth #21 (permanent maxillary left central) since it did not enable a regular root canal treatment approach; the apex was very wide and the dentin walls thin.

The tooth was discolored due to the effect of minocycline, a component of the 3 mix medications used for the revascularization. The tooth was therefore subjected to immediate internal bleaching using sodium perborate, with excellent esthetic results (Figure 4).

All the anterior teeth, the primary and permanent ones, including those with root canal treatment, were covered with composite restorations in the form of artificial celluloid crowns, in order to improve aesthetics and to protect them against bacterial leakage and further erosion.

Stainless steel crowns were adjusted to enable preservation of tooth substance, which achieved a higher vertical dimension while reducing the tendency for caries and thermal sensitivity. An acrylic removable prosthetic device with labial arch and no clasps was selected as the treatment of choice for this case. The advantage of such a device lies in the labial arch, which utilizes the natural labial inclination of the anterior teeth for retention. Since this prosthetic

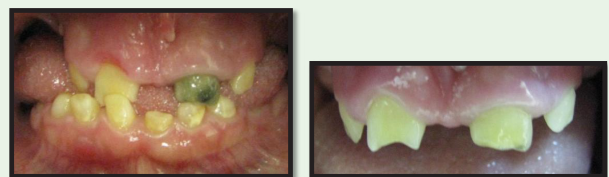

Figure 4: Before and after internal bleaching.

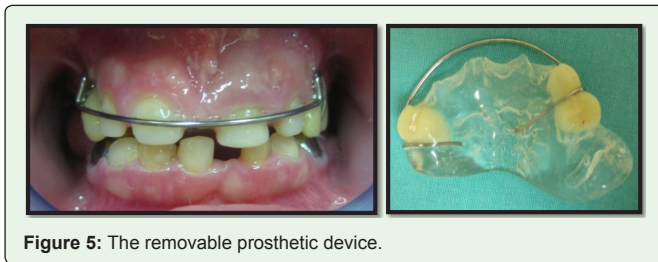


Figure 5: The removable prosthetic device.

device does not have clasps, it does not pose risk of tooth erosion or excessive pressure on a single tooth. The labial arch also allows for distribution of pressure on 4 teeth, thereby substantially reducing the pressure exerted on each tooth compared to the pressure exerted by clasps.

The labial arch was designed to rest on the cervical third of the teeth in order to reduce the pressures exerted on them and to prevent the creation of leverage. The anterior teeth were reconstructed with a slight labial inclination in order to add for the retention, and the distal extension of the removable prosthesis was in accordance to the number of teeth in the lower jaw. In addition, tooth # 26 (permanent maxillary left first molar), which to date had not been functional, was designed to serve as support for the prosthetic device (Figure 5).

Discussion

The described patient suffered from autosomal dominant smooth hypoplastic AI, according to Witkop's classification system [1]. This type of AI is characterized by thin, tough, smooth, and shiny enamel, and a lack of contact points between teeth. Teeth can be white to yellowish-brown in color and the blade or occlusion may be absent if resorption occurred prior to eruption. Such AI is also characterized by congenital hypodontia and a high frequency of intra-alveolar resorption. The described patient presented with all the characteristics of this type of AI.

Aesthetic and functional restoration, and rectification of functional deviation

To improve aesthetic appearance there was a need to extend the anterior teeth. However, due to the functional deviation there was no inter-maxillary space to allow this. The training modules were therefore placed in the articulator in centric relation and the vertical dimension increased by 2 mm to allow space for the future restoration. A diagnostic wax up was done in order to examine future dimensions and relations between the jaws. The design was transferred to the patient's mouth in the new vertical dimension by taking measurements between the free gingiva of the maxillary and mandibular incisors.

In the hypocalcification and hypomaturational AI classes, a substantial increase in the levels of residual amelogenin proteins renders the connection enamel-composite as weak. Preliminary preparation using sodium hypochlorite 5% removes the excess organic matter and may improve the connection to composite [7]. While the described patient suffered from hypoplastic AI, due to damage to the quality of enamel (hypocalcification or hypomaturational), his teeth underwent preparation using sodium hypochlorite prior to the composite reconstruction. A week after the partial prosthetic device was installed, he presented with normal occlusion. The added posterior occlusive surfaces allowed him to chew using his posterior teeth, which eliminated the functional deviation. The appearance of sinus tracts in the absence of caries attests to the high permeability of bacteria through the exposed dentin tubules and underscores the importance of covering all the teeth in the mouth.

In due course, should the premolars remain confined, and their root development stage is 2/3–3/4, surgical exposure will be carried out and an attempt made for them to erupt by orthodontic means. In addition, when tooth # 25 (permanent maxillary left second premolar) will further erupt; a SSC or acrylic crown will be installed on it in order to create an aesthetic cover that can reasonably withstand the occlusive load.

The case study presented demonstrates the main role of the pediatric dentist in treating children suffering from amelogenesis imperfecta. We described how careful planning and multidisciplinary treatment can help overcome significant clinical challenges aesthetically and functionally.

References

1. Witkop C.J.J. Amelogenesis imperfecta, dentinogenesis imperfect and dentin dysplasia revisited, problems in classification. *J Oral Pathol.* 1988; 17: 547-553.
2. Aldred M.J., Savarirayan R., Crawford P.J.M. Amelogenesis imperfecta: a classification and catalogue for the 21st century. *Oral Dis.* 2003; 9: 19-23.
3. Hart T.C., Hart P.S., Gorry M.C., Michalec M.D., Ryu O.H., Uygun C., et al. Novel ENAM mutation responsible for autosomal recessive amelogenesis imperfecta and localised enamel defects. *J Med Genet.* 2003; 40: 900-906.
4. Crawford P.J., Aldred M., Bloch-Zupan A. Amelogenesis imperfecta. *Orphanet J Rare Dis.* 2007; 2: 17.
5. Lindmeyer R.G., Gibson C.W., Wright J.W. Amelogenesis Imperfecta Due to a Mutation of the Enamelin Gene: Clinical Case with Genotype-phenotype correlations. *Pediatr Dent.* 2010; 32: 56-60.
6. Hart P.S., Becerik S., Cogulu D., Emingil G., Ozdemir-Ozenen D., Han S.T. et al. Novel FAM83H mutations in Turkish families with autosomal dominant hypocalcified amelogenesis imperfecta. *Clin Genet.* 2009; 75: 401-404.
7. Venezia R.D., Vadiakas G., Christensen J.R., Wright J.T. Enamel pretreatment with sodium hypochlorite to enhance bonding in hypocalcified amelogenesis imperfecta: case report and SEM analysis. *Pediatr Dent.* 1994; 16: 433-436.