

HISTOPATHOLOGICAL AND HORMONAL ASSESSMENT OF CONTAGIOUS ECHTHYMA DISEASE IN LAMB RAMS

M.A. AL-KHAFAJI¹

University of Anbar, Iraq

Ghusoon A.A.ALNEAMAH

University of Anbar, Iraq

Sabaa Hilal HADI

ASHur University Collage, Iraq

Abstract

Contagious echthyma disease (Orf) is one of the most important, highly infectious and contagious skin viral disease that affects sheep, goats, and wild ruminants, and it is transmitted to humans through contact with infected animals. The current research designed to assisted the histopathological lesions of (Orf) on lamb rams genetalia (testes and epididymis) although hormonal evaluation (testosterone). (PCR) technique used to diagnose the ORF virus taken from clinically infected ram's skin lesion , evaluation of testosterone hormone and histopathological changes of infected ram testes and epididymis (n=20) in al-shomaly province , Babil governorate, Iraq. Results of the clinical examination revealed typical lesions of the disease that started in the form of redness, papules, blisters and crusts in the lips, mouth and scrotum . The results of the molecular diagnosis revealed that the suspected sheep were infected by detecting part of the ORFV037 gene, which has a size of (173) base pair was close to MG712417.1 from China, testosterone hormone assessment revealed sharp decline with significant difference(<.0001) in infected rams compared with non-infected group. Histopathological examination shows presence of interstitial tissue edema and hemorrhage , necrosis and desquamation of epithelial layer in seminiferous tubules with filling the lumen with cellular debris too absent of spermatogenesis and severe vaculation epithelial layer of seminiferous tubules.

The histopathological pictures of epididymis in infected lamb rams shows empty of epididymis tubules lumen with interstitial tissue fibrosis , and desquamations of epithelium lining.

Keywords: *Contagious Echthyma Disease, Testosterone , Histopathology, Testes, Epididymis.*

Introduction

Contagious ecthyma is one of the infectious viral diseases that responsible for the economic losses in the countries of sheep and goat rearing , the etiological agent is ORF virus belongs to the class of parapoxviruses belonging to the poxviridae family (1), which is a ds DNA virus consisting of roughly 64 percent G+C content with 138 kb long genetic material (2). Contagious ecthyma distinguished by its distinctive cutaneous lesions, which occur mostly in the area of the mouth and less frequently in other places, such as the abdomen and inguinal area (3). The disease is extremely infectious and affects small ruminants, both domesticated and wild (4).

ORF virus (ORFV) has a complex host range and, along with its natural hosts, infects a wide range of wild animals, such as the Japanese serov, musk ox, camels, reindeer, seals, and sea lions. (5). The disease also has zoonotic potential, but it is more of an occupational risk to agriculturist, animal attendants and veterinarians, characterized primarily by nodular and papillomatous lesions on the hands, face, and mouth (6).

ORF infection also known as contagious ecthyma, and postural dermatitis. Initially the disease emerges as an erythema after entry through skin abrasions or trauma that transforms into papules later on (7). ORF lesion starts as small, red to blue firm papules that become hemorrhagic flat-topped, and may have an umbilicated center reach 5cm in diameter. . Lesions are typically found around the mouth and nostrils in animals, sometimes arising from the commissures of the lips, lesions can also be seen in the buccal cavity (gums, rough palate, tongue) (8). teat, the skin of the udder and less frequently in the thigh and the inguinal region (7).

In humans, it occurs with painful pustules on the hands, face, and limbs, and the most common lesions are self-limited (9). Disease lesions can also be located in genital organs in adult ewes such as in vulva and skin-vaginal junction, but in rams in preputial orifice (10).

The economic effect of the disease on animals' farmers is due to a decline in productivity and has a direct negative impact on the health of animals. Morbidity can reach up to 100% and the rate of case mortality usually varies from 5-15% (11).

Young animals are seriously impacted, thus stopping suckling. Animals that are badly infected can lose weight and become more vulnerable to secondary bacterial infections . In young animals, morbidity is very high and mortality is generally poor. Sheep are vulnerable to repeated infection and there are also chronic infections present (12). The maximum productivity of animals and the market value of meat, leather and wool may also be affected by contagious ecthyma lesions (13).

Methodology:

Animals and study design (sample collection) for this study was conducted to examine 20 local rams breeds 8 months in AL-shomaly province, Babil governorate, Iraq. Represents flock groups. All animals showed different clinical manifestations belong to contagious ecthyma. Clinically, 10 healthy local rams were considered as controls. The collection of samples was extended from February to March, 2022. Complete clinical examinations were applied to all animals. samples were collected from each animal's skin, blood and testes, illustrated in the attached work experimental design, as follows:

- Biopsy of the skin of the lips 2microgram was placed in a sterile test tube containing glycerin and a phosphate buffer solution in a ratio of (1:1) ml for molecular study.
- Biopsy of the testes 1cm was placed in formalin at a concentration of 10%, for the purpose of histopathological examination.
- blood samples were collected for testosterone hormone estimation.

Hormonal assay:

Levels of testosterone hormones in sera was assessed by using commercial available Minividus apparatus obtained from (BIOMEREUX). The result was reported as nanoogram /milliliter (ng/ml). The test was carried out according to the manufacture assay protocol.

Histopathological examination:

Specimens with dimension 1x1x1 cm were taken from testis, epididymis and the technique done according to (14).

Molecular detection of ORF viruses

Preparing primers

Before using the primers, they were lyophilized. They dissolved in free deionized distilled water to make a stock solution with a final concentration of 100 pmol/μl and stored it at -20°C to make a work primer immediately suspended with a concentration of 10 pmol/μl. Then, 10μl of the stock solution were mixed with 90μl of free deionized distilled water to make a final volume of 100μl with final work concentration of 10 pmol/μl.

Samples collection

Viral DNA was extracted from skin scrape tissue samples were collected from clinical examined rams infected naturally with ORF virus from al-shomaly province Babil governorate, Iraq. Samples were collected in sterile containers under aseptic conditions containing 1ml glycerin and 1ml phosphate buffer saline and transported as soon as to store in -20°C refrigerator until use for viral genomic DNA extraction.

Extraction of viral DNA

Viral DNA was extracted by using QIAamp MinElute Virus Spin Kit, Germany, following the manufacturer's instructions. Extracted DNA was stored at - 20C until being used.

Polymerase chain reaction (PCR)

In order to identify the viral nucleic acid, all extracted viral nucleic acids were examined by electrophoresis. a Nano drop spectrophotometer, used for assist DNA concentration and then the DNA purity was measured based on the absorption of the sample at wavelengths of 260 nm. The readout and DNA purity were determined by a ratio equal to 50µg/1µl.

DNA was amplified by performing PCR technique using (Go Taq Green Master mix (M7822), Promega/USA) following the manufactures instructions. primer pairs were designed to identify important ORF virus including confirmed ORF virus primer, which is amplicon size around (173bp) part of ORFV037 gene (15) (F2: 5'-CCAGGGGAAGTTCAGGTACG -3' and R2: 5'- ACTACGAAACTGTGGGCGAG - the amount used in the PCR reaction mixture was done according the standard application Go Taq® G2 Green Master Mix, Promega, USA.

Statistical Analysis

The experiment was designed according to a Complete Randomized Design (CRD) and the ready-made statistical program SAS was used to analyze the effect of transactions on the studied traits (16). The significant differences between the means of the studied traits were tested according to Duncan's polynomial test (17).

Results:

Molecular diagnosis results:

PCR technique was used to confirm and detect ORF virus with both genes. All samples (n=20) was positive in PCR assay for ORF at ≈173bp part of ORFV037 gene.

Testosterone hormone result:

The testosterone hormone showed decline in titration in infected group with ORF (0.0929b) comparing with titration of testosterone hormone in non- infected group (0.208 a) (figure , 1).

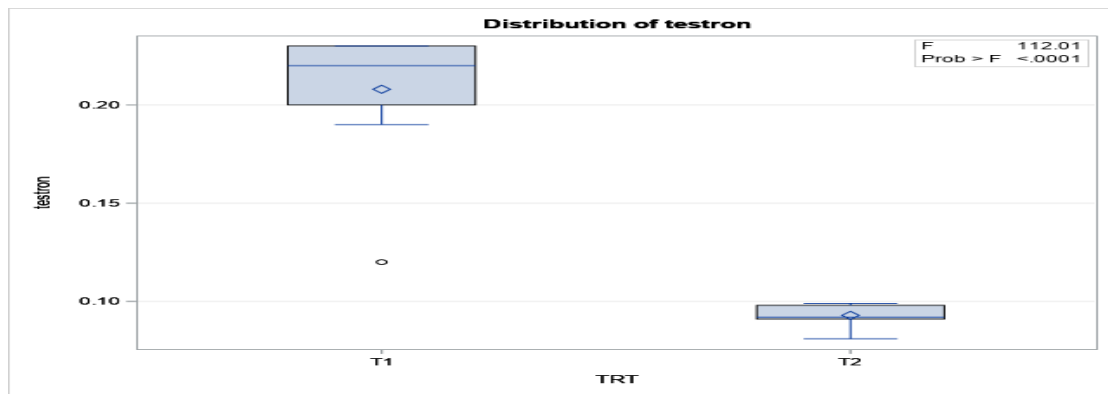


Fig.(1):Show relative testosterone hormone with non- infected (T1) from infected (T2) groups.

Histopathological examinations results

Testes and Epididymis:

The histopathological examination of rams control group showed normal structure of the testes and epididymis section which manifested by normal histological structure (figure 2 and 3) including testes regular seminiferous tubules with active leydig cells and complete spermatogenesis furthermore the epididymis histopathological picture revealed filling with sperms.

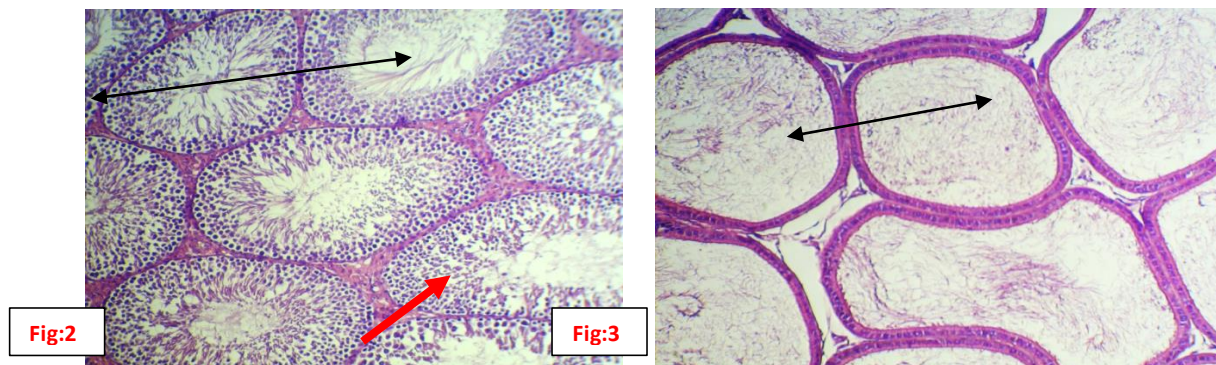


Fig:2 Histological section the testes of non- infected lamb rams shows normal all layer of spermatogenesis process of seminiferous tubules with sperms in their lumen (\longleftrightarrow) and active of leydig cells(\rightarrow) fig(3):Histological section of non-infected ram show epididymis filling with sperms(\longleftrightarrow) (H&E stain 400X)

The histopathological pictures of infected rams testes shows interstitial tissue edema and hemorrhage , necrosis and desquamation of epithelial layer in seminiferous tubules with filling the lumen with cellular debris and absent of spermatogenesis and severe vaculation epithelial layer of seminiferous tubules and basement membrane lining only by single cells(figures: 7 and 8) respectively.

While the histopathological pictures of infected rams epididymis shows empty of epididymis tubules lumen with interstitial tissue fibrosis , and desquamations of epithelium lining (figure:4,5and 6) respectively.

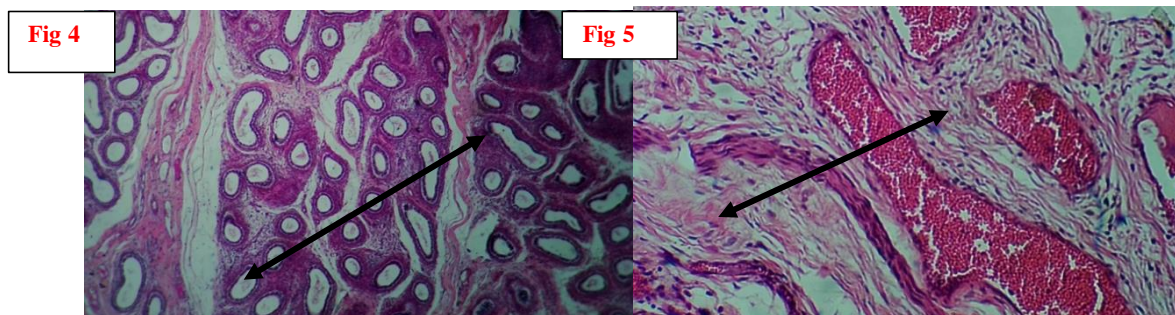
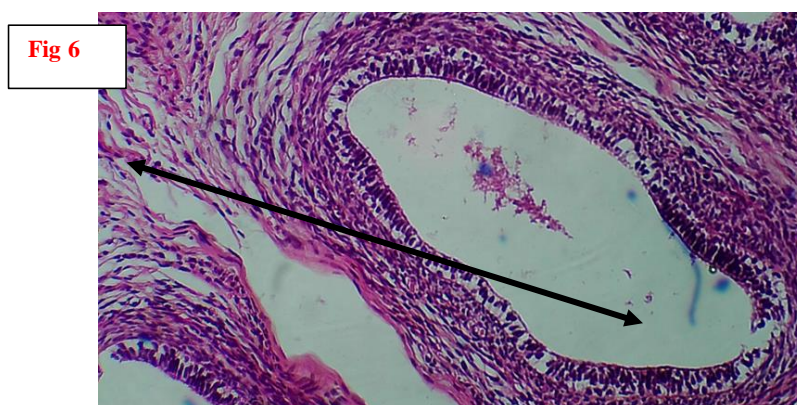


Fig4: Histological section of infected lamb ram with contagious echthyma 8 months age shows empty of epididymis tubules lumen with interstitial tissue fibrosis (\longleftrightarrow) ((100X), congestion of tunica albogena blood vessels () with fibrosis of interstitial tissue Fig(5) (400X) (H& E stain)



Fig(6): Histological section of infected ram epididymis with contagious echthyma 8months age shows fibrosis of interstitial tissue and desquamations of epithelium (\longleftrightarrow) (H& E stain 200X)

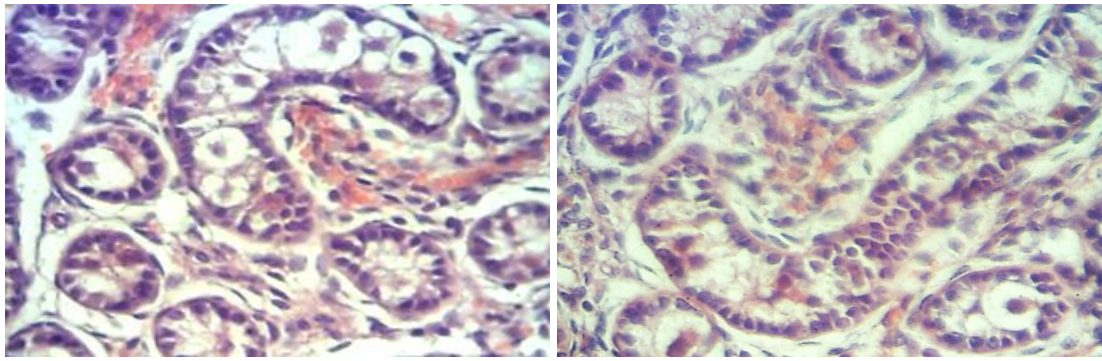


Fig 7: Histological section of infected lamb ram testes infected with contagious echthyma 8 months age shows interstitial tissue edema and hemorrhage (\longleftrightarrow) (200X) , (Fig:8) shows shape variation of seminiferous tubules, necrosis and desquamation of epithelial layer with filling the lumen with cellular debris (\longleftrightarrow)(H& E stain 400X).

Discussion:

Hormonal and histopathological examination:

The results of the present study express that ORFV causes hormonal decline conducted for lesions presented in testes and epididymis such as interstitial orchitis with epididymitis, the result agree with (18) who suggested that viral infection-induced oxido-inflammatory response results in testicular damage, through atrophy of the seminiferous tubules and reduced Leydig with Sertoli cells mass. This is maintained by reduced circulatory testosterone, reduced sperm motility, impaired spermatogenesis, DNA fragmentation, lipid peroxidation, elicit sperm cells necrobiosis. (19) demonstrated that ORFV can also produce a homolog of the anti-inflammatory cytokine, interleukin (IL-10) which acts as a local suppression of immunity. Interleukin-10 is predominantly an immunosuppressive cytokine that down regulates T-cell mediated immune responses by altering the function of antigen presenting cells and inhibiting production of some cytokines, notably inflammatory cytokines such as IL-8 and TNF- α as well as the T-cell lymphokine interferon- γ . Virus-mediated male reproductive dysfunction has been associated with oxido-inflammatory damage. Viruses trigger inflammatory responses, up-regulation of pro-inflammatory cytokines and leukocyte infiltration resulting in urethritis, prostatitis, epididymitis, and orchitis due to innate immune system motivation (20). Though viral infections combated innate ability which mediates the inflammatory response, moreover inducing free radicals generation as Reactive oxygen species and redox imbalance with consequent oxidative damage (21). Furthermore, ROS-dependent oxidative stress that activated by pro-inflammatory cytokines, in turn further exaggerate inflammatory response, resulting in vicious cycle of oxido-inflammatory response (22). The testis and spermatozoa plasma membranes raised polyunsaturated fatty acids makes them readily prone to ROS-driven oxidation, resulting in lipid peroxidation, loss of testicular and sperm cell membrane integrity, and raised non-specific permeability of ions (23). Subsequently, destruction of the

testicular and sperm cell membrane, subjected nuclear chromatin to oxidative damage, inducing DNA fragmentation, base modification, testicular and sperm cell apoptosis (24).

Conclusions

this study indicates that ORF virus infection although systemize as a skin disease , it can cause decrease in sexual hormone (testosterone) and pathological lesions of orchitis and epididymitis of lamb rams leading to infertility caused by complete aspermatogenesis in the testes and epididymis, which empties sperm.

References

1. Zhang, K., Lu, Z., Shang, Y., Zheng, H., Jin, Y., He, J. and Liu, X. (2010). Diagnosis and phylogenetic analysis of ORF virus from goats in China: a case report. *Virology Journal*, 7(1):78.
2. Li, W., Ning, Z., Hao, W., Song, D., Gao, F., Zhao, K. and Luo, S. (2012). Isolation and phylogenetic analysis of ORF virus from the sheep herd outbreak in northeast China. *BMC veterinary research*, 8(1):229.
3. Karki M, Venkatesan G, Kumar A, Kumar S and Bora DP. (2019). Contagious ecthyma of sheep and goats: A comprehensive review on epidemiology, immunity, diagnostics and control measures. *Veterinarski arhiv.*, 89(3):393-423.
4. Nandi S, De UK and Chowdhury S. (2011). Current status of contagious ecthyma or orf disease in goat and sheep: a global perspective. *Small Rumin. Res.*, 96(2): 73-82. DOI: [10.1016/j.smallrumres.2010.11.018](https://doi.org/10.1016/j.smallrumres.2010.11.018)
5. Sharma AK, Venkatesan G, Mathesh K, Ram H, Ramakrishnan MA and Pandey AB. (2016). Occurrence and identification of contagious ecthyma in blackbuck. *Virus Disease*, 27(2):198-202.
6. Zhang K, Liu Y, Kong H, Shang Y and Liu X. (2012). Human infection with ORF virus from goats in China. *Vector-Borne and Zoonotic Diseases*, 14(5):365-367. doi: [10.1089/vbz.2013.1445](https://doi.org/10.1089/vbz.2013.1445)
7. Vikoren T, Lillehaug A, Åkerstedt J, Bretten T, Haugum M and Tryland M. (2008). A severe outbreak of contagious ecthyma (ORF) in a free-ranging musk ox (*Ovibos moschatus*) population in Norway. *Veterinary microbiology*, 127(1-2):10-20. doi: [10.1016/j.vetmic.2007.07.029](https://doi.org/10.1016/j.vetmic.2007.07.029)
8. de la Concha-Bermejillo, J Guo, Z Zhang, D Waldron. (2003). Severe persistent ORF in young goats. *J of vet diagn invest.*, 15(5):423-431. DOI: [10.1177/104063870301500504](https://doi.org/10.1177/104063870301500504)
9. Suhail Al-Salam, Norbert Nowotny, Mohammed Rizwan Sohail, Jolanta Kolodziejek, Thomas G Berger. (2008). Ecthyma contagiosum (ORF) - report of a human case from the United Arab Emirates and review of the literature. *Journal of cutaneous pathology*, 35(6):603-607. doi: [10.1111/j.1600-0560.2007.00857.x](https://doi.org/10.1111/j.1600-0560.2007.00857.x)
10. D J McKeever, H W Reid, N F Inglis, A J Herring. (1987). A qualitative and quantitative assessment of the humoral antibody response of the sheep to ORF virus infection. *Veterinary microbiology*, 15(3):229-241. DOI: [10.1016/0378-1135\(87\)90077-0](https://doi.org/10.1016/0378-1135(87)90077-0)
11. Mombeni EG, Mousavi MB, Ranjbaran I, Chanani ZZ, Hoseini M, Davoudi A and Mombeini MG. (2012). Prevention and treatment of contagious ecthyma in sheep and goat by goat pox vaccine in Khuzestan province, Iran. *Bull Environ Pharmacol Life Sci.*, 1(12):69-72.
12. Gelaye E, Achenbach JE, Jenberie S *et al.* (2016). Molecular characterization of orf virus from sheep and goats in Ethiopia, 2008–2013. *Virol J.*, 13, 34 doi: [10.1186/s12985-016-0489-3](https://doi.org/10.1186/s12985-016-0489-3)

13. Sadiq, M.A., Abdullah, F.F.C., Bitrus, A.A.A., Balakrishnan, K.N.B., Lila, M.M.A., Abba, Y. and Chung, E.L.T.(2017).Severe persistent case of contagious ecthyma (ORF) in goats. Journal Animal Health Production, 5(1):24-28. [doi:10.14737/journal.jahp/2017/5.1.24.28](https://doi.org/10.14737/journal.jahp/2017/5.1.24.28)
14. Abbas, A.A., Faraj, M.K. and Abed, A.R. (2012).Some biochemical and histopathological effects of different oral doses Ochrotoxin A in male rats. Proceeding of the Eleventh Veterinary Scientific Conference. IJVM., special issue, (36): 182-189.
15. Yasmeeen Jasim Mohammed(2021). Pathological and Immunohistochemical Changes in the Small Ruminants Naturally Infected with Contagious Ecthyma (ORF Virus). A Dissertation Submitted to the Council of the College of Veterinary Medicine/University of Baghdad, as a Partial Fulfillment of the Requirements for the Degree of Doctorate of Philosophy in Science of Veterinary Medicine/Veterinary Pathology.
16. SAS. Statistical Analysis System, User's Guide. Statistical.(2012).Version 9.1th ed. SAS. Inst. Inc. Cary. N.C. USA.
17. Duncan,D.B. (1955).Multiple ranges multiple F-tests. Biometrics, 11(1): 1 – 42. doi.org/10.2307/3001478.
18. Akhigbe RE, Dutta S, Hamed MA,Ajayi AF, Sengupta P and Ahmad G. (2022). Viral Infections and MaleInfertility: A Comprehensive Review of the Role of Oxidative Stress.Front. Reprod. Health, 4:782915 . doi.org/10.3389/frph.2022.782915
19. Bennett, J.R., Lateef, Z., Fleming, S.B., Mercer, A.A. and Wise, L.M. (2016) . Orf virus IL-10 reduces monocyte, dendritic cell and mast cell recruitment to inflamed skin. Virus Res., 2.213:230-237.doi: 10.1016/j.virusres.2015.12.015.
20. Jenabian M-A, CostiniukCT, MehrajV, Ghazawi FM, Fromentin R, Brousseau J, et al. (2016). Immune tolerance properties of the testicular tissue as a viral sanctuary site in ART-treated HIV-infected adults. Aids., 30:2777–86.
21. Akhigbe RE, Ajayi LO, Adelakun AA, Olorunnisola OS, Ajayi AF. (2020).Codeine-induced hepatic injury is *via* oxidao-inflammatory damage and caspase 3-mediated apoptosis. *Mol Biol Rep.*, 47:9521–30.
22. Makker K, Agarwal A, Sharma R.(2009). Oxidative stress and male infertility. Indian J Med Res., 129:357–67.
23. Ajayi AF,Akhigbe RE,Ram SK,et al. (2021). Management of COVID-19 among health care givers:an Afro-Asian perspective. Asian J.Epidemiol., 14:11–21.
24. Zribi N, Chakroun NF, Elleuch H, Abdallah FB, Ben Hamida AS, Gargouri J, et al.(2011). Sperm DNA fragmentation and oxidation are independent of malondialdehyde. *Repro Biol Endocrinol.*, 9:47.