

Clinical prognostic factors in newly diagnosed glioblastoma

Ionela Bizu¹, Oana Gabriela Trifanescu^{2,3}, Mihai-Teodor Georgescu^{2,3},
Maria Iuliana Gruia, Rodica Anghel^{2,3}

¹"OncoFort" Hospital, Bucharest, Romania

²"Al. Trestioreanu" Institute of Oncology, Bucharest, Romania

³"Carol Davila" University of Medicine and Pharmacy, Bucharest, Romania

ABSTRACT

Introduction. Glioblastoma multiforme is one of the most aggressive primary brain tumor, with a poor prognosis.

Aim. This study assesses the outcomes of patients with newly diagnosed glioblastoma treated in our hospital with multimodal treatment consisting of surgical resection, concurrent chemoradiotherapy with Temozolomide and adjuvant six cycles Temozolomide, depending on clinical prognostic factors.

Materials and methods. Clinical data from 47 glioblastoma patients treated in OncoFort Hospital from January 2015 to December 2017 were analyzed. The following data were extracted from medical records of the patients: age, gender, Karnofsky Performance Status, tumor location, size of tumor, type of surgery, postoperative treatment and survival time between diagnosis and time of last contact.

Results. Our statistical analysis showed a longer survival among patients with of Karnofsky Performance Scale ≥ 80 , tumor dimension < 4 cm, gross-total resection and extended chemotherapy with Temozolomide for more than 6 cycles.

Conclusions. GBM remains an incurable disease. The multidisciplinary approach is recommended to optimize results for this malady.

Keywords: glioblastoma, survival, chemoradiotherapy, temozolomide

Abbreviations

Glioblastoma multiforme = GBM, Karnofsky Performance Status = KPS Temozolomide = TMZ, Progression free survival = PFS, Magnetic resonance imaging = MRI, Computer tomography = CT, Overall survival = OS

INTRODUCTION

Glioblastoma multiforme (GBM) is the most aggressive malignant glioma in adults, with a recurrence rate of 90% (1).

Though the diagnosis of a GBM is rare, with an incidence rate only 2-3 cases per 100,000 persons in the Europe and North America, it is the most common type of brain tumor with an extremely poor prognosis (2).

The incidence rate of GBM increases with age, with highest rates between 75 and 84 years (3).

Most common location of GBM is hemispheres of brain, often in the frontal and temporal lobes and much less commonly can appear in the brainstem, cerebellum or the spinal cord (4,5).

Current standard therapy is based on a multidisciplinary approach, where the surgery is the first step in the treatment, while oncological therapy insures increase of survival (6).

Without treatment, patients diagnosed with this disease survive three months and patients treated with optimal therapy, including surgical resection, chemoradiotherapy and adjuvant chemotherapy,

Corresponding author:

Ionela Bizu

E-mail: ionelabizub@gmail.com

Article History:

Received: 10 May 2019

Accepted: 25 May 2019

have a median survival of approximately 12-16 months (6,7,8).

Uncontrolled proliferation, diffuse infiltration and high genomic instability explain the inevitable resistance to standard therapy and relapse (9,10).

MATERIALS AND METHODS

In this study, we retrospectively analyzed 47 medical records of patients with confirmed GBM and treated in our department between January 2015 and December 2017.

Inclusion criteria were: adult patient, histological proven diagnosis of GBM, Karnofsky Performance Status (KPS) of 60 or above.

The patients underwent surgical intervention aiming at maximal safe resection of the gross disease and if this was not feasible, patients had at least biopsy for establish the diagnosis.

Postoperative chemoradiotherapy with Temozolomide (TMZ) (75 mg/mp), for six weeks and six cycles of chemotherapy consisting of TMZ (150-200 mg/mp day 1-5, q4w), were planned.

Radiotherapy aims a total dose of 60 Gy, conventional fractionation through three-dimensional conformal radiotherapy (3D-CRT) or intensity modulated radiotherapy (IMRT) techniques.

All patients were assessed neurological, clinically, with complete blood test on presentation, then weekly during chemoradiotherapy and 3-4 weeks after the completion of treatment.

Progression free survival (PFS) was calculated between the date of initial surgery and progression or recurrence on MRI/ CT imaging, or the date of last contact or death.

Overall survival (OS) was measured between the date of diagnosis and the date of last follow-up or death resulting from any cause.

STATISTICAL ANALYSIS

Statistics was done through “IBM SPSS statistics” version 20.0 program. Median PFS and median OS were calculated using the Kaplan-Meier method. The log-rank test was used to compare differences between survival curves. P-values less than 0.05 were considered to be statistically significant.

RESULTS

Forty-seven consecutive patients were included in the study, 27 male (57.44%) and 20 females (42.55%). The sex ratio was 1.35. The median patient age at diagnosis was 57 years (range: 32-78) (Fig. 1).

Frontal lobe location was most common (n=18; 38.29%), followed by temporal lobe (n=14; 29.78%), parietal lobe (n=7; 14.89%), others (n=3; 6.38%). Multiple tumors were observed in 5 patients (10.63%). Mean tumor size as measured by preoperative MRI was 4.59 cm (range: 1.1-7.2).

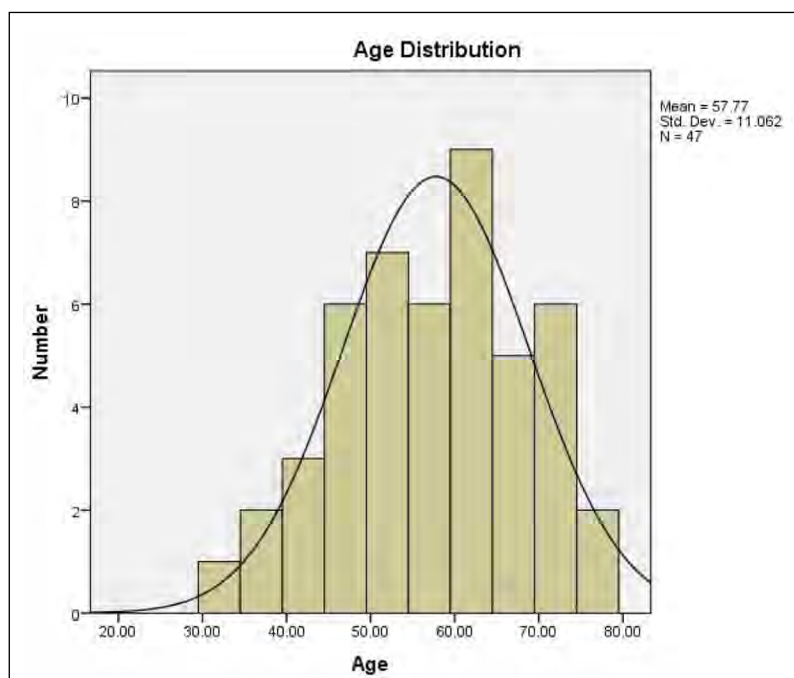


FIGURE 1. Age Histogram

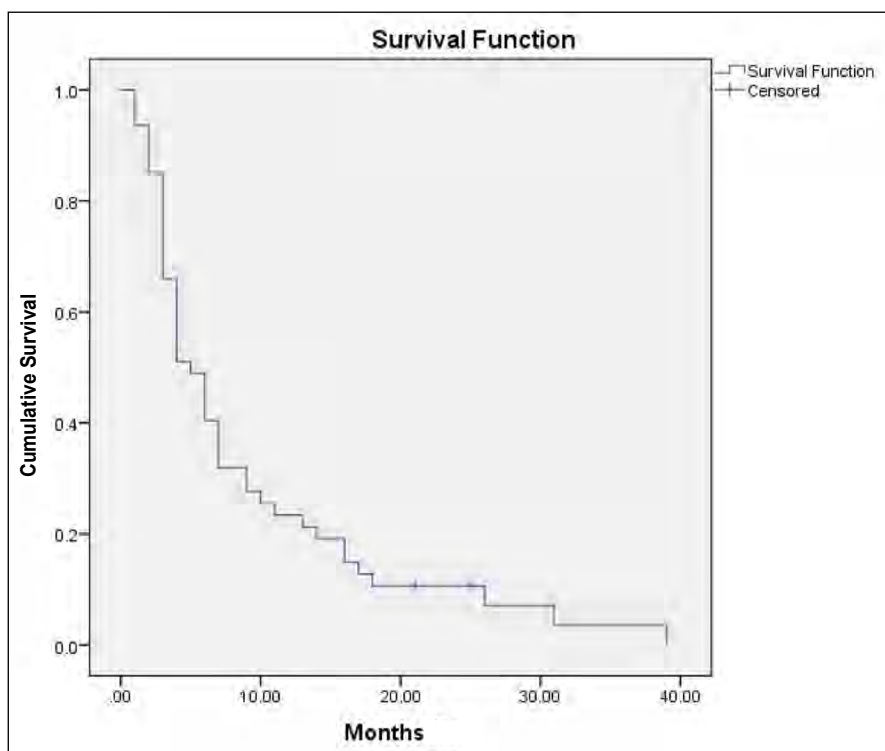


FIGURE 2. Progression free survival curve for all 47 patients evaluated

We had the following histopathological distribution: 70.21% conventional glioblastoma, 19.14% glioblastoma with oligodendroglioma component, 6.98% small cell glioblastoma; gliosarcoma and giant cell glioblastoma had a frequency of 2.12% each.

Gross total resection was possible in 15 (31.91%) patients and subtotal resection was done in 26 (55.31 %), in 6 patients (12.76%) surgery could not

be performed and the patient underwent only biopsy. The Karnofsky index value was 60 in 5 patients (10.63%), 70 in 10 patients (21.27%) and ≥ 80 in 32 patients (68.08%).

The mean total dose of radiation was 57.39 Gy.

After chemoradiotherapy, the mean number of adjuvant TMZ cycles delivered to patients was 5.27 (range 0-28).

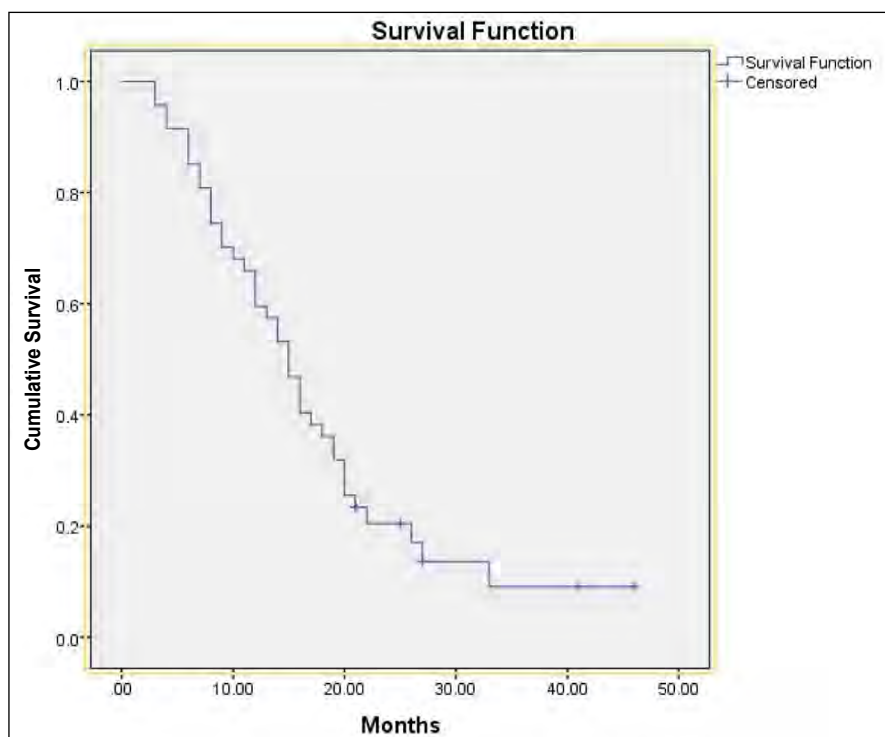


FIGURE 3. Overall survival curve for all 47 patients evaluated

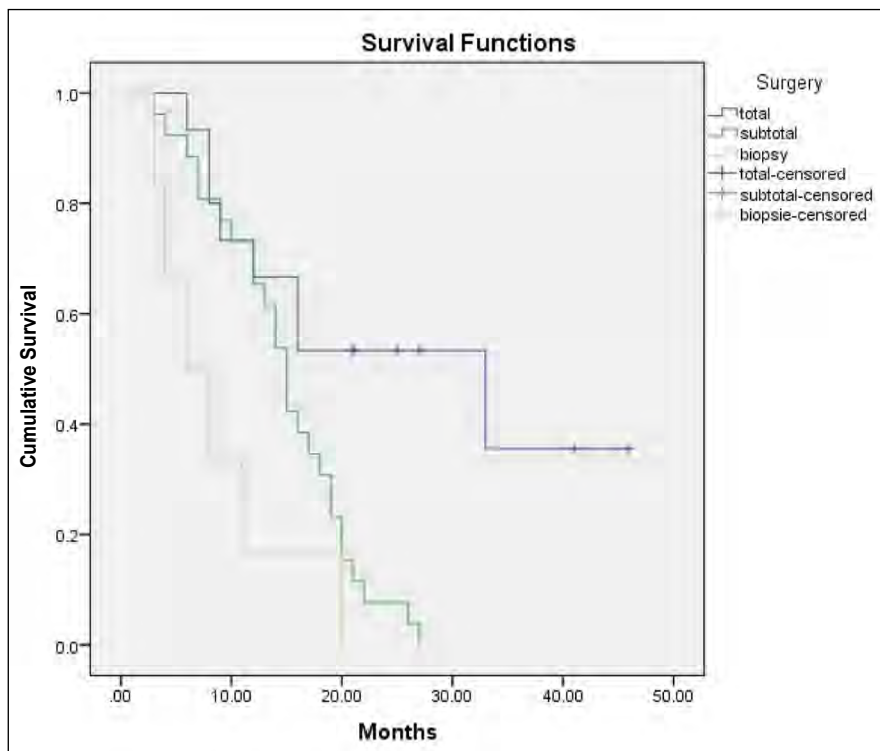


FIGURE 4. Multivariate analysis – Overall Survival total ablation vs. subtotal ablation vs. biopsy

The median PFS was 5 months (95% CI 3.321-6.679) (see Figure 2).

The progression free survival rate at 6 months was 48.93%.

In all patients, the median OS was 15 months (95% CI 12.48-17.51) (Fig. 3), and the first and

second year survival rate was 65.95% and 19.4% respectively.

Multivariate analysis regarding the outcome showed advantage for total ablation vs. subtotal ablation and biopsy ($p < 0.004$, $p < 0.003$) (Fig. 4).

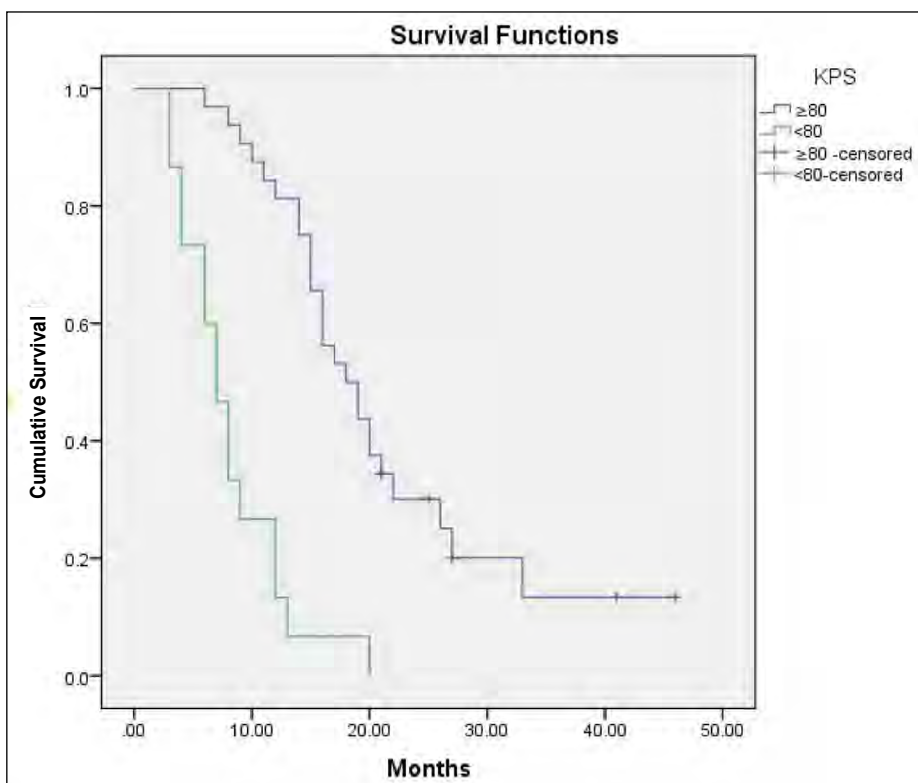


FIGURE 5. Overall survival distribution by Karnofsky Performance Scale

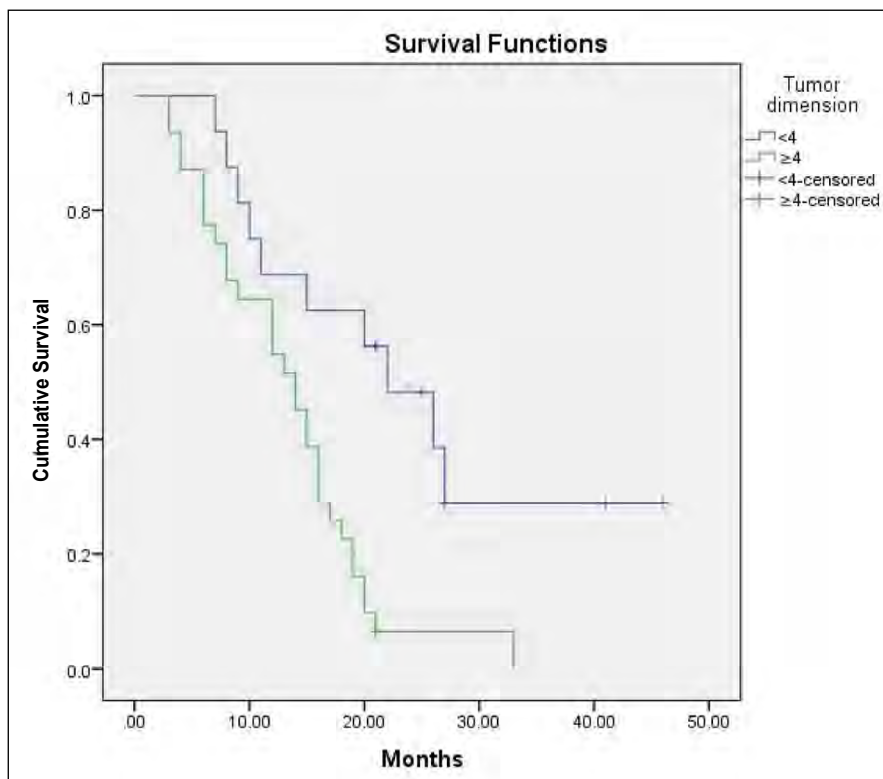


FIGURE 6. The relation between tumor dimension on the preoperative radiological images and overall survival

The longest estimated median survival was calculated in patients with Karnofsky Performance Scale ≥ 80 (18 months, $p < 0.001$) (Fig. 5).

In our study, no significant difference was found in the survival of patients of at least 50 years old than that of below 50 years of age.

Our results show that bigger tumor size at pre-operative MRI are associated with worse prognosis. As shown in fig. 6, using log rank analysis, patients with smaller tumors (<4 cm) had a median OS of 22 months compared to 14 months among patients with the larger tumors (≥ 4 cm), $p = 0.002$.

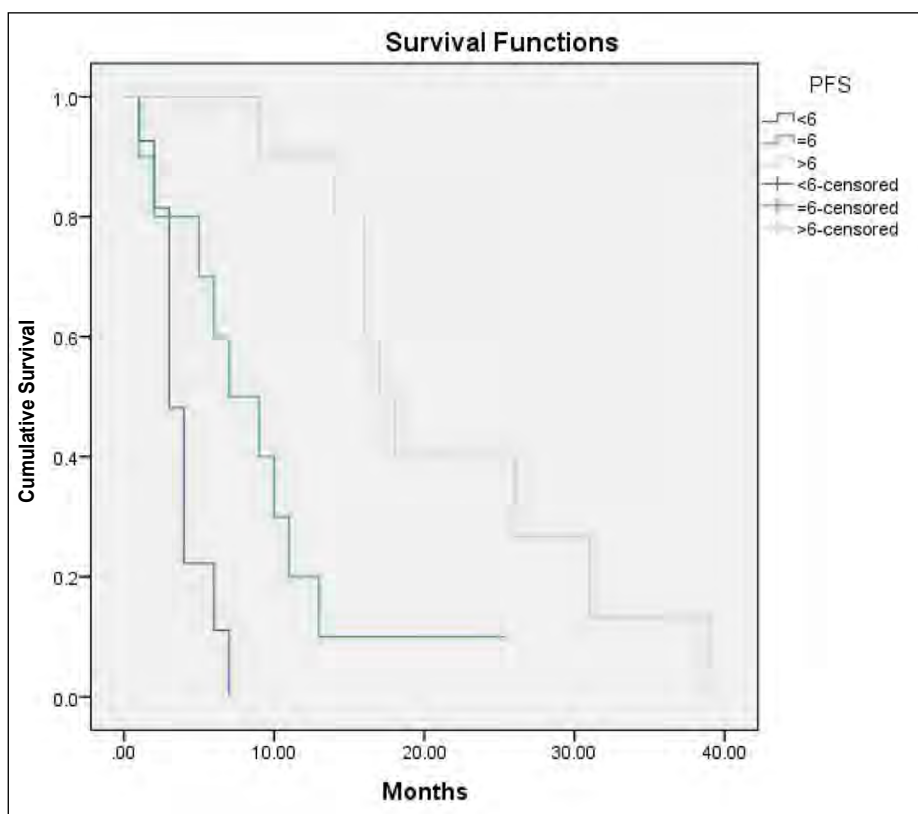


FIGURE 7. A – Overall Survival: < 6 cycles, 6 cycles, >6 cycles TMZ;

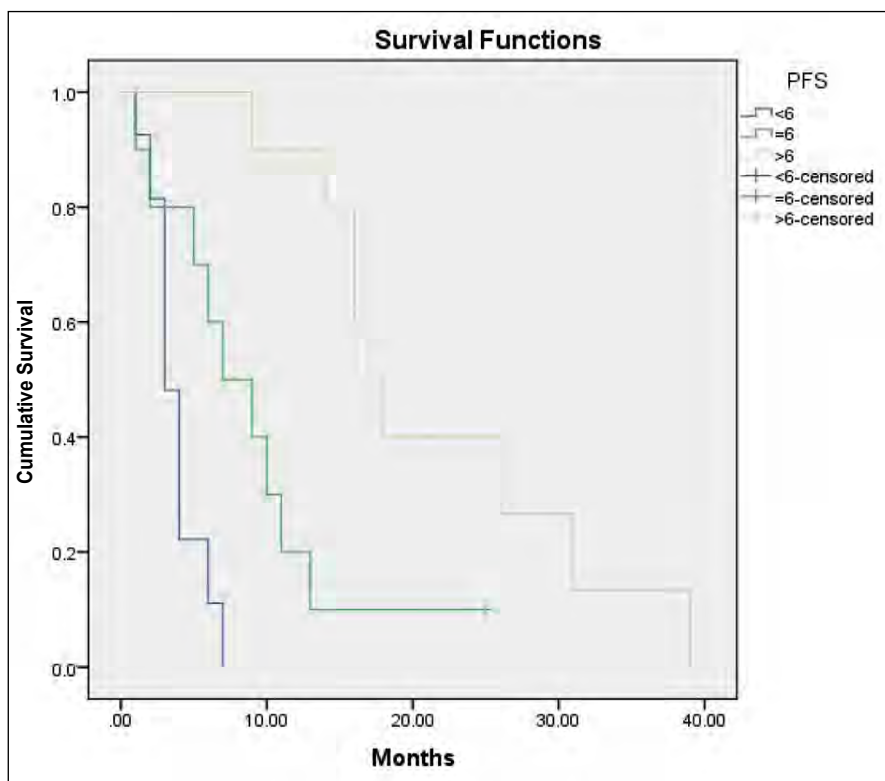


FIGURE 7. B – Progression free survival: < 6 cycles, 6 cycles, >6 cycles TMZ

There was no statistically significant association observed between overall survival and age of diagnosis (log-rank test; $p=0.517$), gender (log-rank test; $p=0.752$), multicentric GBM at MRI (log-rank test; $p=0.202$) and histopathological subtypes (log-rank test; $p=0.989$).

After concomitant treatment from total number of patients, 12 didn't continue chemotherapy with TMZ (10 patients due to disease progression, 2 due to death), 15 received less than six cycles, 10 received six cycles and 10 received more than six cycles.

As shown by Kaplan-Meier curve analysis, patients who received long-term TMZ treatment had longer OS and PFS than patients receiving standard treatment ($p<0.029$, $p<0.004$, respectively) (Fig. 7 A, B).

The most frequent hematologic complications were neutropenia, presented in 10 cases (21.27%), leucopenia in 8 (17.02%), thrombocytopenia in 11 (23.40%).

Due to severe hematologic toxicities, one patient had to stop the concomitant treatment with radiotherapy and TMZ earlier.

DISCUSSIONS

Postoperative radiation therapy alone was standard treatment until 2005, when the results of a large,

randomized, multicentric phase III trial that included 573 patients with newly diagnosed GBM from 85 centers changed the standard of care.

This trial, known as the Stupp regimen, reported a median overall survival of 14,6 months (95% CI 13.2 – 16.8) for the radiotherapy plus TMZ group versus 12.1 months (95% CI 11.2 – 13.0) for the radiotherapy alone group.

Overall survival was 61.1% at one year, 26.5% at 2 years, with TMZ and radiotherapy, versus 50.6%, and 10.4 % with radiotherapy alone

Until now, the Stupp protocol is the only alternative that have managed to significantly increase the survival of these patients (6).

This is a retrospective study with median follow-up of 14.85 months in which our patients underwent adjuvant chemoradiotherapy with TMZ in the Stupp regimen.

The median age of our patients was 57 years, which is very close of median age from Stupp study (56 years).

Also, our median PFS and OS of 5 and 15 months, respectively, are comparable to the Stupp trial results showing a median PFS and OS of 6.9 and 14.6 months, respectively, in the treated patients with concurrent and adjuvant TMZ.

Previous studies proved that there are various factors related to the patient, tumor and treatment that affects the outcomes (11).

So, we analyzed the impact of these factors (age, gender, performance status, tumor dimension, tumor location, extension of surgery, concurrent TMZ, adjuvant chemotherapy) on the result.

In other similar studies, the information regarding the benefit of extended surgery are opposite (12).

The survival rate in patients with GBM is improved by extension of surgery, so, complete resection led to the longest survival of 33 months, followed by 15 months for partial resection and 6 months for patients with biopsy.

On univariate analysis, high KPS score (≥ 80) and tumor dimension were two significant prognostic factors correlated with OS ($p=0.001$, $p=0.002$, respectively).

In our study, the variables the patient's gender, histopathologic sub-type, tumor location and age did not appear to have a significant effect on survival.

Furthermore, we noticed that patients receiving more than six cycles of TMZ had a significant

longer survival which is consistent with results of Seiz et al. study (13).

CONCLUSIONS

Despite the aggressive treatment, recurrence and death are inevitable.

In our analysis, total surgery led to a standalone significant improvement of survival.

Maximal resection should be performed whenever possible, and results in significantly longer survival time.

Also, administration of more than 6 cycles of chemotherapy should be taken into consideration in daily practice.

This study proves that the efficiency of our treatment is at least similar with the ones mentioned in other studies from worldwide.

Source of founding

This work received financial support through the project entitled "CERO – Career profile: Romanian Researcher", grant number POS-DRU/159/1.5/S/135760, co-financed by the European Social Fund for Sectoral Operational Programme Human Resources Development 2007-2013.

Conflict of interest: none declared

REFERENCES

- Weller M, Cloughesy T, Perry JR et al. Standards of care for treatment of recurrent glioblastoma – are we there yet? *Neuro Oncol.* 2013 Jan; 15(1): 4–27. doi: 10.1093/neuonc/nos273
- Deorah S, Lynch CF, Sibenaller ZA et al. Trends in brain cancer incidence and survival in the United States: Surveillance, Epidemiology, and End Results program, 1973 to 2001. *Neurosurg Focus.* 2006;20:1–7. doi: doi.org/10.3171/foc.2006.20.4.E1
- Ostrom QT, Gittleman H, Fulop J et al. CBTRUS Statistical Report: Primary Brain and Central Nervous System Tumors Diagnosed in the United States in 2008-2012. *Neuro Oncol.* 2015;17 Suppl 4:iv1-iv62. doi: 10.1093/neuonc/nov189.
- Tamaki T, Eguchi T, Sakamoto M et al. Glioblastoma multiforme of the cerebellum in an elderly man. *J Chin Medical Association* 2004; 67: 301-304.
- Engelhard HH, Villano JL, Porter KR et al. Clinical presentation, histology, and treatment in 430 patients with primary tumors of the spinal cord, spinal meninges, or cauda equina. *J. Neurosurg.* 2010, Spine, vol. 13 (1) : 67–77, doi:10.3171/2010.3.SPINE09430.
- Stupp R, Mason WP, van den Bent MJ et al. Radiotherapy plus concomitant and adjuvant temozolomide for glioblastoma. *N Engl J Med* 2005; 352: 987–996. doi: 10.1056/NEJMoa043330.
- Malmstrom A, Gronberg BH, Marosi C et al. Temozolamide versus standard 6-weeks radiotherapy versus hypo fractionates radiotherapy in patients older than 60 years with glioblastoma. The Nordic randomized phase 3 trial. *Lancet Oncol.* 2012;13 (9):916–926. doi:10.1016/S1470-2045(12)70265-6
- Erpolat OP, Akmansu M, Goksel F et al. Outcome of newly diagnosed glioblastoma patients treated by radiotherapy plus concomitant and adjuvant temozolomide: A long-term analysis. *Tumori.* 2009;95 (2):191–197
- Colombo MC, Givero C, Faggiano E et al. Towards the personalized treatment of glioblastoma: Integrating patient-specific clinical data in a continuous mechanical model. *PLoS One.* 2015 ;10 (7): e0132887. doi: 10.1371/journal.pone.0132887
- Wilson TA, Karajannis MA, Harter DH. Glioblastoma multiforme: State of the art and future therapeutics. *Surg Neurol Int.* 2014; 5:64–62. doi: 10.4103/2152-7806.132138.
- Nizamutdinov D, Stock EM, Dandashi JA et al. Prognostication of Survival Outcomes in Patients Diagnosed with Glioblastoma. *World Neurosurg.* 2018 ;109:e67-e74. doi:10.1016/j.wneu.2017.09.104.
- Hart MG, Grant R, Metcalfe SE. Biopsy versus resection for high grade glioma (Review). *Cochrane Database Syst Rev* 2011(3). doi:10.1002/14651858
- Seiz M, Krafft U, Freyschlag CF et al. Long-term adjuvant administration of temozolomide in patients with glioblastoma multiforme: Experience of a single institution. *J Cancer Res Clin Oncol.* 2010; 136(11):1691-1695. doi: 10.1007/s00432-010-0827-6.